

MANAGING MUSCULOSKELETAL SARCOMAS – GUIDELINES

Musculoskeletal sarcomas are relatively uncommon. The developments in the last few years including advances in imaging, adjuvant modalities and surgical techniques have greatly improved not only the local management of these lesions but have also seen increased patient survival compared to the dismal results of a few decades earlier. In spite of these exciting advances, the uncommon nature of these lesions and the paucity of exposure to these tumors results in most clinicians approaching them with trepidation and uncertainty. We need to dispel age old myths and create awareness about the current concepts in musculoskeletal oncology.

A clinical or radiological suspicion of a musculoskeletal sarcoma should result in a referral to a hospital/centre where there are qualified radiologists, pathologists and orthopaedic/surgical oncologists with the necessary expertise to diagnose and plan the management of these lesions (this need not be the ultimate treating centre though that would be the ideal scenario).^{1,2}

Suspicious signs suggestive of a sarcoma:

The commonest symptom of a primary bone sarcoma is non mechanical pain. The presence of pain or a palpable mass arising from any bone should be viewed with suspicion. A plain X ray in two planes is the first investigation of choice. The presence of any of the following on the X-ray is suggestive, but not diagnostic of a bone sarcoma: (i) bone destruction, (ii) new bone formation, (iii) periosteal swelling, (vi) soft tissue swelling.³ Further investigation is then warranted.

The presenting symptoms and signs of soft-tissue sarcomas are nonspecific. They commonly present as a painless, slow-growing mass. While sarcomas in the extremities may present earlier, diagnosis of sarcomas involving the pelvic cavity may be delayed. Their location deep within the body precludes palpation of the tumor mass early in the course of the disease. Consequently, these tumors often reach tremendous size prior to diagnosis without causing overt symptoms. Any soft tissue lump exhibiting any of the following clinical features should be considered to be malignant until proved otherwise : (i) increasing in size, (ii) size >5 cm, (iii) deep to the deep fascia, (iv) painful. The more of these clinical features present, the greater the risk of malignancy with increasing size being the

best individual indicator.⁴ An important dictum may be that “*any tumor found deep to the deep fascia or larger than 5 cm should be regarded as a soft tissue sarcoma until proven otherwise.*”



After a diagnosis is proposed based on the clinico radiologic picture a biopsy is planned. Biopsy is to be done only after all local imaging is completed (refer specific guidelines). Ideally the biopsy of patients with a possible sarcoma should only be carried out at a tumor treatment centre. In case this is not possible a telephonic cross consult with an orthopaedic/surgical oncologist or an identified “tumor treatment” centre would help in planning the biopsy site. In most cases a core needle biopsy is adequate (it may need to be image guided depending on anatomical location of lesion). A poorly performed biopsy may not only fail to provide a diagnosis; it may compromise limb salvage, lead to more extensive surgery than initially planned and have a negative impact on overall survival.⁵ In Ewing’s sarcoma and soft tissue tumors immunohistochemistry confirmation of the histopathological diagnosis is desirable. Additional cytogenetic and molecular studies may also be necessary to reach a diagnosis in certain musculoskeletal tumors.



A sarcoma once diagnosed should be referred to an identified “tumor treatment” centre with the requisite multidisciplinary facilities for the integrated care of these lesions. This may be a medical college / regional cancer centre which has the available facilities, Referral may be based on the patient’s preference and geographical location.



Additional serological and staging investigations include:

- In osteosarcoma and Ewing's sarcoma though there are no specific laboratory tests for diagnosis some may be of prognostic value; e.g. alkaline phosphatase (ALP) and lactate dehydrogenase (LDH)³

To rule out metastasis:

- In osteosarcoma and chondrosarcoma a CT scan chest and a bone scan
- In Ewing's sarcoma a PET CT Scan / or if PET not available : Bone scan + CT Thorax & Bone marrow aspiration & biopsy⁶
- In soft tissue tumors a X ray chest / CT Scan (CT chest recommended in high grade sarcomas) and USG abdomen pelvis in myxoid / round cell liposarcoma, angiosarcoma, epithelioid sarcoma and synovial sarcoma⁴



Treatment schedules involving multidisciplinary care as indicated are planned. Administration of adjuvant modalities (chemotherapy /radiotherapy) may be carried out at centres closer to the patient's residence (based on the patient's preference and geographical location) keeping in mind the logistics of time duration of non surgical neoadjuvant and adjuvant treatment modalities. Chemotherapy and radiotherapy are important components of the treatment and should be carried out by appropriate specialists and not by the surgeon. Though orthopaedic/surgical oncology skills may not be widely prevalent, the facilities for adequate chemotherapy and radiotherapy are more easily accessed at multiple locations.

Unless an amputation is advised for oncologic clearance (this can be performed by the local surgeon based on the level recommended by the sarcoma management team), the patients should undergo definitive resection of their sarcoma by a surgeon trained in orthopaedic/ surgical oncology with the adequate infrastructure available to handle these complex resections and reconstructions. Such facilities would include ready availability of allied specialties like a plastic surgeon, vascular surgeon and occasionally a general

surgeon and urosurgeon in case of pelvic tumors. A well stocked blood bank and an adequately equipped intensive care unit are also necessary. An accredited bone bank is of immense benefit in oncologic reconstructions. Establishing and maintaining a formal bone bank requires especially trained personnel. Immediate post operative rehabilitation should be ideally under the supervision of a rehabilitation expert who works in close conjunction with the operating team. Subsequently, a detailed written rehabilitation schedule can be given to the patient to be carried out under the supervision of local rehabilitation personnel with further telephonic consultation if necessary.

Continuing adjuvant therapy (chemotherapy /radiotherapy) as indicated after surgery is critical to ensure overall disease control and patients must be explained the importance of the same. Surveillance after therapy at regular intervals is important. The logistics of the same can be worked out on a case by case basis after discussion with the patient, treating team and referring physician.



Surveillance:

There are no published data supporting specific policies for follow-up of surgically treated patients with localized disease. Relapses most often occur to the lungs. The risk assessment based on tumor grade, tumor size and tumor site may help in choosing the routine follow-up policy. High risk patients generally relapse within 2–3 years, while low-risk patients may relapse later, although it is less likely. The best method of follow-up has not been established. Although the use of MRI to detect local relapse and CT to scan for lung metastases is likely to pick up recurrence earlier, it is yet to be demonstrated that this is beneficial or cost effective compared with clinical assessment of the primary site and regular chest X-rays.⁷ Local examination, chest and local imaging every 3 months for first 2 years, every 6 months for next 3 years and annually after year 5 is suggested. Extended surveillance may be necessary to identify and address potential late effects of surgery, radiation and chemotherapy for long term survivors

Treatment Overview:

Also refer specific guidelines – **Osteosarcoma** : page 9 - 11
Ewing's sarcoma : page 12 - 14
Chondrosarcoma : page 15 - 16
Soft tissue sarcoma : page 17 - 19

Surgery:

Surgery of the primary tumor should be performed only after adequate preoperative staging and planning in a MDT. The goal is to achieve adequate oncologic clearance. Conventionally, quantitative parameters are used to define resection margins. A marrow margin of 3 cms as evaluated on the T1 weighted MRI image is usually considered adequate clearance in bone lesions whereas a 2 cm margin away from the tumor is what most surgeons should aim to achieve in soft tissue lesions.⁸ Due to anatomical constraints it is not always possible to achieve these absolute distances. The margin can be quantitatively less in the case of resistant anatomic barriers, such as muscular fasciae, periosteum, joint capsule, tendon, tendon sheath, epineurium, vascular sheath and cartilage.⁹

Decisions about the optimal surgical procedure (i.e. limb salvage or amputation) should be made on an individual case to case basis depending on various factors (patient's age, tumor site, size, extent and response to neoadjuvant therapy). The type of surgical reconstruction will depend on patient and surgeon choice, experience and facilities available following discussion of the risks and benefits of different options.

Chemotherapy:

Multiagent chemotherapy is the standard of care in osteosarcoma and Ewing's sarcoma. Doxorubicin, cisplatin, high-dose methotrexate, etoposide and ifosfamide have demonstrated antitumor activity in osteosarcoma. Most current protocols incorporate these agents in 3 or 4 drug combinations.¹⁰ Agents considered most active in Ewing's sarcoma include doxorubicin, cyclophosphamide, ifosfamide, vincristine, dactinomycin, and etoposide. Most current protocols are based on four to six drug

combinations.³ The above chemotherapy combinations should be administered with adequate supportive care. Chemotherapeutic drugs may result in renal, cardiac, and auditory dysfunction in addition to common side effects like myelo suppression, infection and neuropathy. Patients must therefore have baseline renal function testing and assessment of cardiac function as well as an audiogram (in case of treatment with cisplatin). Sperm banking is recommended for male patients of reproductive age while female patients would benefit with counseling by a fertility physician.

Currently there is inadequate evidence to recommend adjuvant chemotherapy as standard for all patients of soft tissue sarcoma.¹¹ It may be considered in a select population of high grade extremity sarcoma, > 5 cm or recurrent high grade tumors using doxorubicin alone or a combination of doxorubicin plus ifosfamide.¹²

Radiotherapy:

Osteosarcoma and chondrosarcoma being relatively radio resistant have a limited role for radiotherapy. Radiotherapy is only used as definitive treatment of a primary tumor if there is no acceptable surgical option.¹³

Ewing's sarcoma being a radiation-sensitive tumor, radiotherapy is utilised as part of management. It may be used as definitive local therapy if surgery is not an option, with curative intent or may be used in combination with surgery, for patients who have had a poor histological response to chemotherapy, or when there are concerns regarding surgical resection margins. The dose administered depends on the resection margins and response to chemotherapy.¹⁴⁻¹⁶ Portals are individually tailored for every patient and target volumes are MRI based to include both, the bone and soft tissue component.

Radiotherapy has a definite role in the management of soft tissue sarcomas especially high grade tumors > 5 cms. Radiotherapy may be in the form of intraoperative brachytherapy, external beam radiotherapy or a combination of the two.¹⁷ The dose of external beam radiotherapy can range from 45 Gy when combined with brachytherapy to 70 Gy when external beam radiotherapy alone is used in excisions with macroscopic residual disease.

References:

1. Jansen-Landheer ML, Krijnen P, Oostindier MJ, Kloosterman-Boele WM, Noordijk EM, Nooij MA, et al. Improved diagnosis and treatment of soft tissue sarcoma patients after implementation of national guidelines: a population-based study. *Eur J Surg Oncol* 2009;35:1326-32.
2. Federman N, Bernthal N, Eilber FC, Tap WD. The multidisciplinary management of osteosarcoma. *Curr Treat Options Oncol* 2009;10:82-93.
3. Grimer R, Athanasou N, Gerrand C, Judson I, Lewis I, Morland B, et al. UK Guidelines for the Management of Bone Sarcomas. *Sarcoma*;2010:317462.
4. Grimer R, Judson I, Peake D, Seddon B. Guidelines for the management of soft tissue sarcomas. *Sarcoma*;2010:506182.
5. Pollock RC, Stalley PD. Biopsy of musculoskeletal tumours--beware. *ANZ J Surg* 2004;74:516-9.
6. Kneisl JS, Patt JC, Johnson JC, Zuger JH. Is PET useful in detecting occult nonpulmonary metastases in pediatric bone sarcomas? *Clin Orthop Relat Res* 2006;450:101-4.
7. Cool P, Grimer R, Rees R. Surveillance in patients with sarcoma of the extremities. *Eur J Surg Oncol* 2005;31:1020-4.
8. Novais EN, Demiralp B, Alderete J, Larson MC, Rose PS, Sim FH. Do surgical margin and local recurrence influence survival in soft tissue sarcomas? *Clin Orthop Relat Res*;468:3003-11.
9. Kawaguchi N, Ahmed AR, Matsumoto S, Manabe J, Matsushita Y. The concept of curative margin in surgery for bone and soft tissue sarcoma. *Clin Orthop Relat Res* 2004:165-72.
10. Whelan J, Seddon B, Perisoglou M. Management of osteosarcoma. *Curr Treat Options Oncol* 2006;7:444-55.
11. Pervaiz N, Colterjohn N, Farrokhyar F, Tozer R, Figueredo A, Ghert M. A systematic meta-analysis of randomized controlled trials of adjuvant chemotherapy for localized resectable soft-tissue sarcoma. *Cancer* 2008;113:573-81.
12. Adjuvant chemotherapy for localised resectable soft tissue sarcoma in adults. *Cochrane Database Syst Rev* 2000:CD001419.
13. Schwarz R, Bruland O, Cassoni A, Schomberg P, Bielack S. The role of radiotherapy in osteosarcoma. *Cancer Treat Res* 2009;152:147-64.

14. Schuck A, Ahrens S, Paulussen M, Kuhlen M, Konemann S, Rube C, et al. Local therapy in localized Ewing tumors: results of 1058 patients treated in the CESS 81, CESS 86, and EICESS 92 trials. *Int J Radiat Oncol Biol Phys* 2003;55:168-77.
15. Paulussen M, Ahrens S, Dunst J, Winkelmann W, Exner GU, Kotz R, et al. Localized Ewing tumor of bone: final results of the cooperative Ewing's Sarcoma Study CESS 86. *J Clin Oncol* 2001;19:1818-29.
16. Donaldson SS. Ewing sarcoma: radiation dose and target volume. *Pediatr Blood Cancer* 2004;42:471-6.
17. Yang JC, Chang AE, Baker AR, Sindelar WF, Danforth DN, Topalian SL, et al. Randomized prospective study of the benefit of adjuvant radiation therapy in the treatment of soft tissue sarcomas of the extremity. *J Clin Oncol* 1998;16:197-203.

OSTEOSARCOMA

Osteosarcoma is a primary malignant tumor in which the neoplastic cells produce osteoid matrix. It is the most frequent primary cancer of bone. The majority arise in adolescence, but some are linked to other pathologies (Paget's disease) occurring in the sixth and seventh decades of life. Osteosarcoma usually arises in the metaphysis of an extremity long bone, most commonly around the knee though it can occur anywhere in the axial or appendicular skeleton. Conventional osteosarcoma, a high-grade malignancy, accounts for the majority of osteosarcoma. Other high-grade types are telangiectatic, small cell, and high-grade surface osteosarcoma. Low-grade central and parosteal osteosarcoma are low-grade malignancies, while periosteal osteosarcoma is an intermediate-grade osteosarcoma.

BIOPSY

- Biopsy diagnosis is mandatory
- Biopsy to be done only after all local imaging is completed
- In most cases a core needle biopsy is adequate (it may need to be image guided depending on anatomical location of lesion)
- Ideally performed at centre which will do definitive management of disease

SEROLOGICAL INVESTIGATIONS

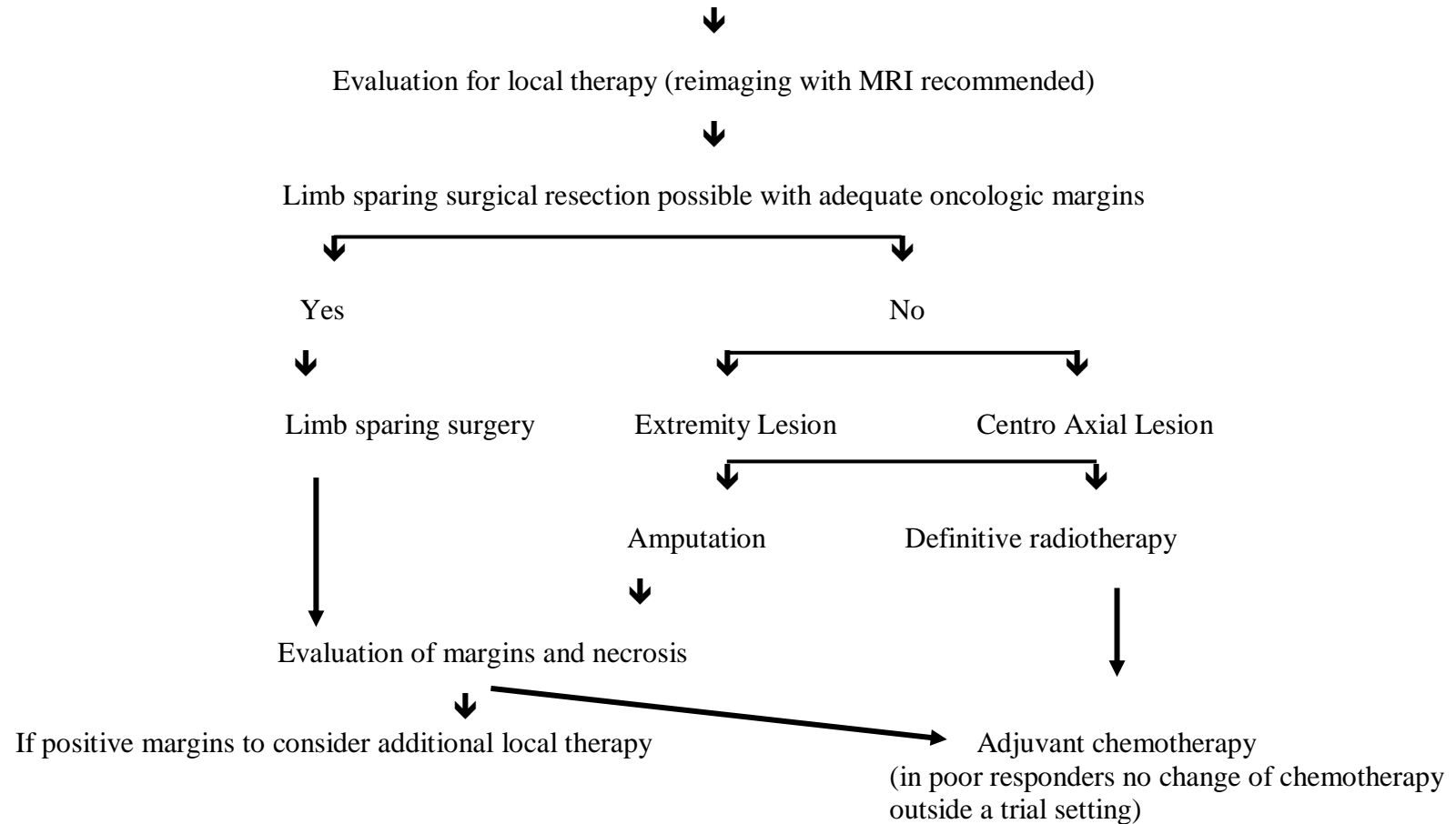
- Though there are no specific laboratory tests for diagnosis some maybe of prognostic value; e.g. alkaline phosphatase (ALP) and lactate dehydrogenase (LDH)

STAGING

- Local X Ray
- MRI
- CT scan chest
- Bone scan

HIGH GRADE OSTEOSARCOMA – NON METASTATIC AT PRESENTATION

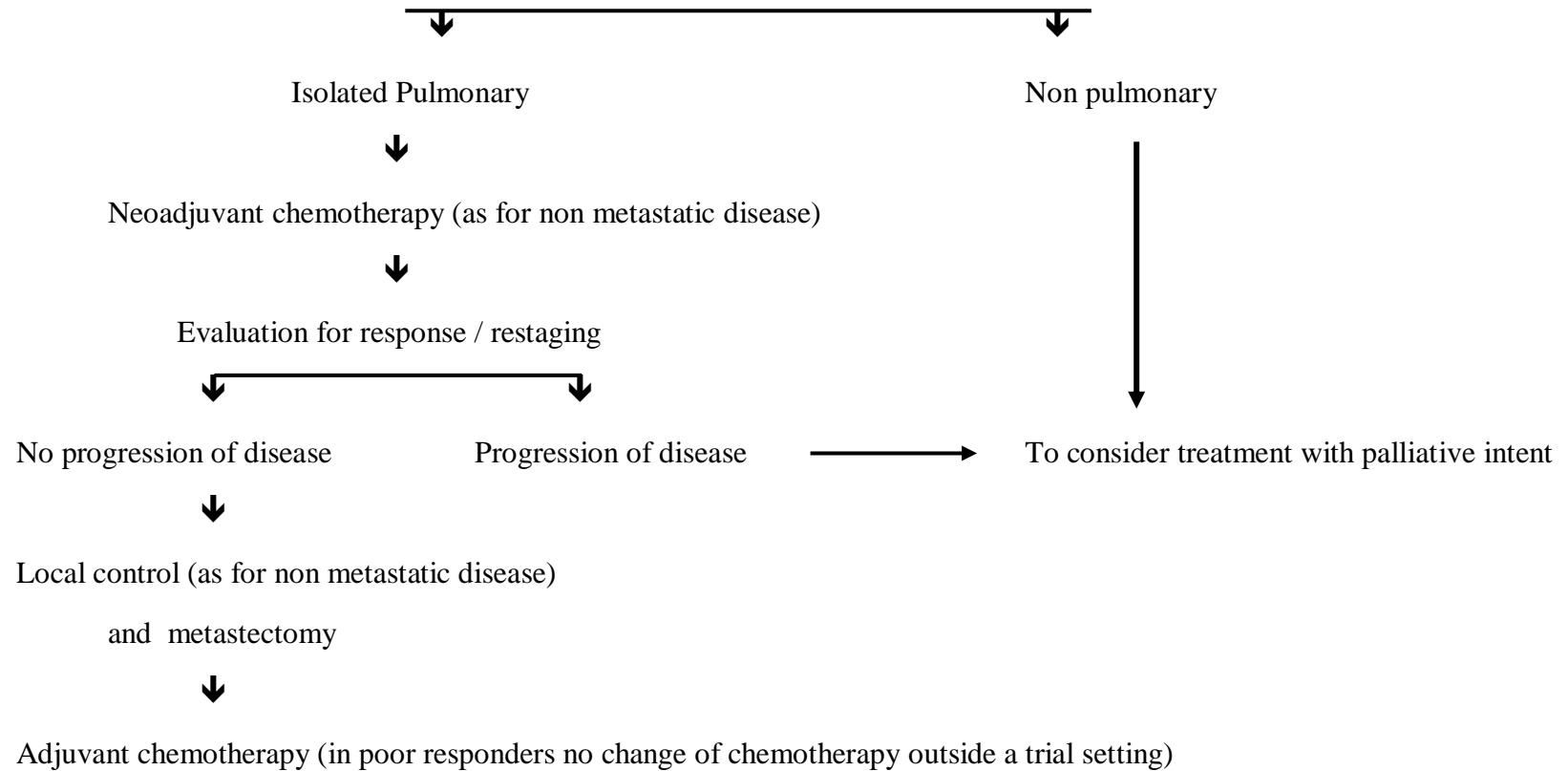
Neoadjuvant chemotherapy (chemotherapy is multiagent) 3 cycles prior to local control



Osteosarcomas diagnosed as low grade on initial biopsy (parosteal / low grade intramedullary) are treated with wide excision only. If after definitive surgery a high grade component is identified they receive multiagent adjuvant chemotherapy

Parosteal osteosarcomas are currently treated similar to high grade osteosarcomas

HIGH GRADE OSTEOSARCOMA – METASTATIC AT PRESENTATION



EWING'S SARCOMA

Ewing's sarcoma (including primitive neuroectodermal tumor of bone/PNET) is the second most common primary malignant bone cancer in children and adolescents, but is also seen in adults. The most frequent sites of involvement are the long bones and pelvis. All forms of Ewing's sarcoma are high-grade tumors

BIOPSY

- Biopsy diagnosis is mandatory
- Biopsy to be done only after all local imaging is completed
- In most cases a core needle biopsy is adequate (it may need to be image guided depending on anatomical location of lesion)
- Ideally performed at centre which will do definitive management of disease
- Immunohistochemistry confirmation desirable , may need additional cytogenetic and molecular studies

SEROLOGICAL INVESTIGATIONS

- Though there are no specific laboratory tests for diagnosis some maybe of prognostic value; e.g. alkaline phosphatase (ALP) and lactate dehydrogenase (LDH)

STAGING

- Local X Ray
- MRI
- PET CT Scan / or if PET not available : Bone scan + CT Thorax & Bone marrow aspiration & biopsy

EWING'S SARCOMA – NON METASTATIC AT PRESENTATION

Induction chemotherapy (chemotherapy is multiagent) for at least 9 weeks prior to local therapy



Evaluation for local therapy between week 9 and 12 (reimaging with MRI recommended)



Limb sparing surgical resection possible with adequate oncologic margins



Yes

No



Surgery



Extremity Lesion

Centro Axial Lesion



Definitive Radiotherapy vs Ablative surgery (Discuss with patient and multidisciplinary treating team)

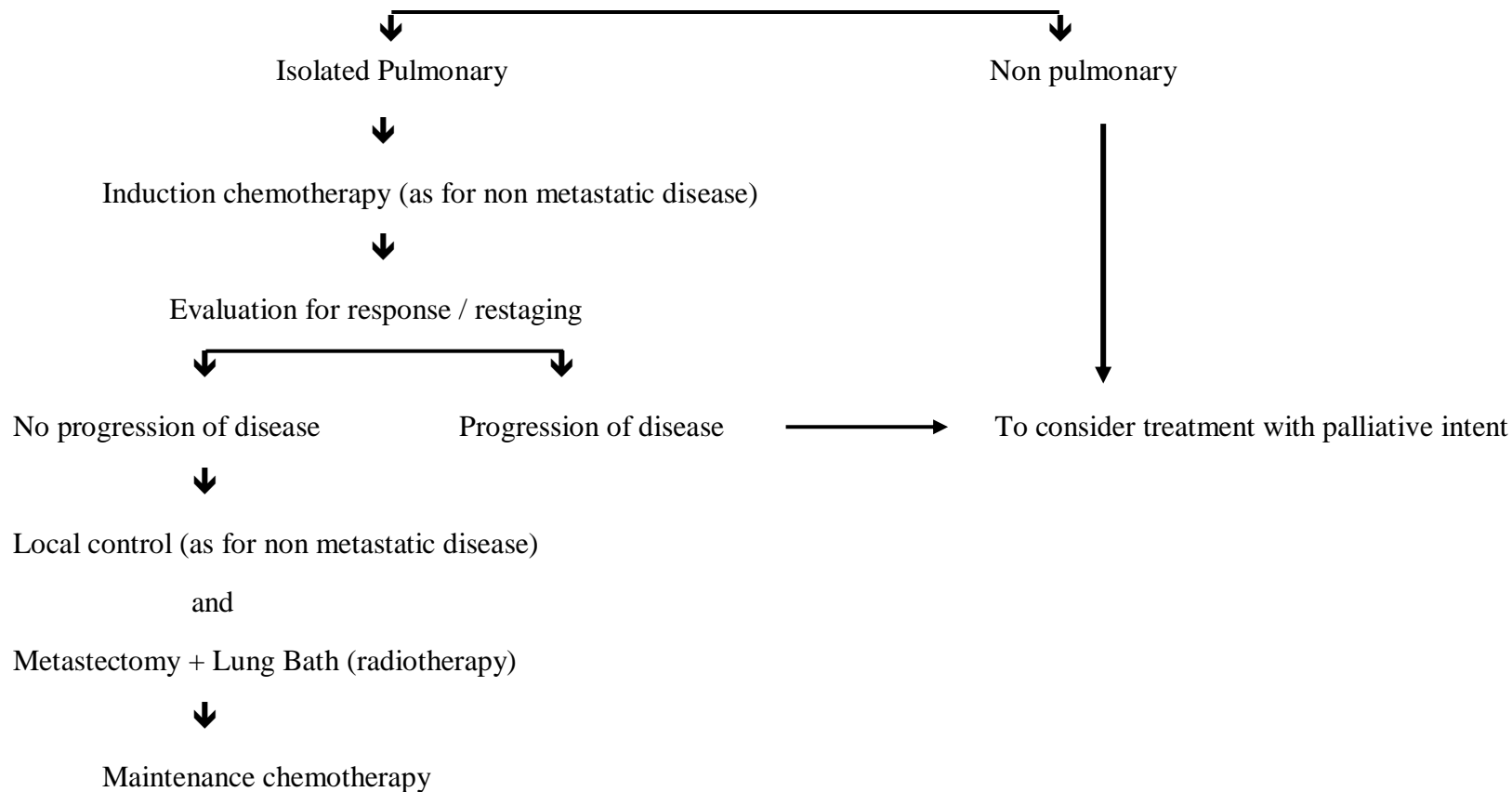
Definitive Radiotherapy

Indications for post operative radiotherapy

	Negative margins	Positive margins
≥ 90 % necrosis	No adjuvant RT	Adjuvant RT
< 90 % necrosis	Discuss in multidisciplinary clinic	Adjuvant RT

Maintenance chemotherapy

EWING'S SARCOMA – METASTATIC AT PRESENTATION



CHONDROSARCOMA

Chondrosarcoma is one of the most common bone sarcomas of adulthood, characterized by the production of tumor cartilage. Though commonest in the long bones they also occur in flat bones such as pelvis, rib, and scapula. Secondary chondrosarcomas can arise in preexisting benign lesions such as osteochondroma and enchondroma. Rarer subtypes of chondrosarcoma include mesenchymal chondrosarcoma and clear cell chondrosarcoma. Conventional chondrosarcomas may rarely “dedifferentiate” into a very high-grade tumor with a dismal prognosis so called dedifferentiated chondrosarcoma.

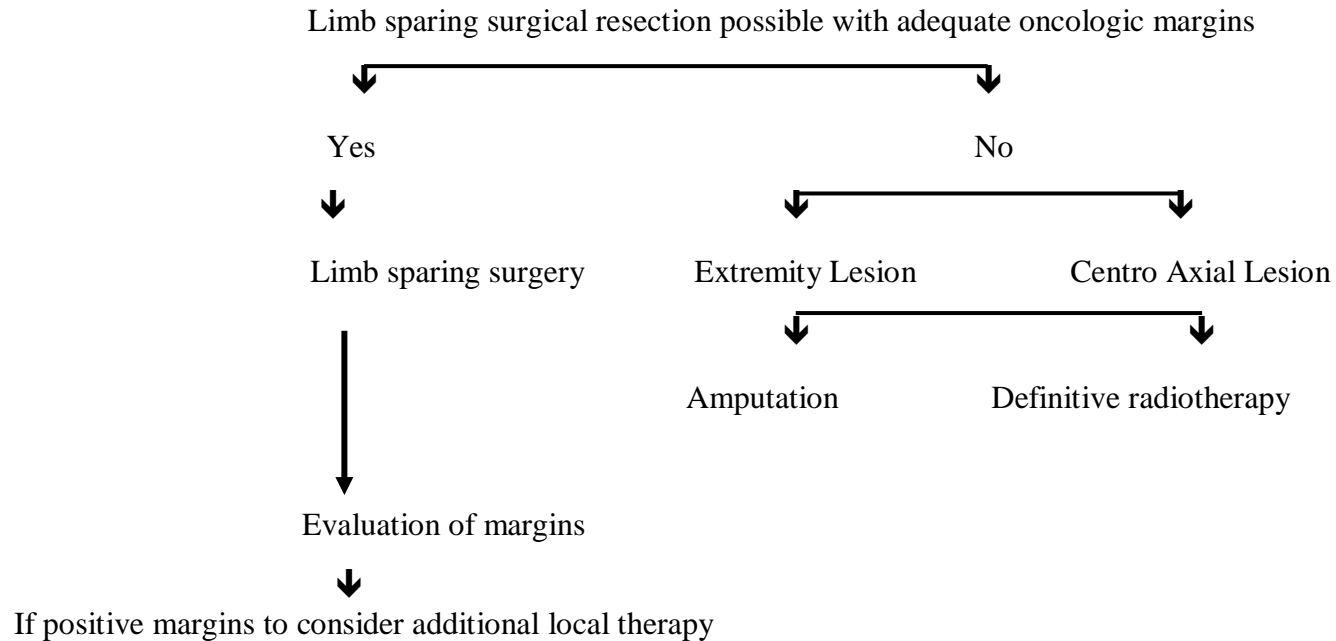
BIOPSY

- Biopsy diagnosis is mandatory
- Biopsy to be done only after all local imaging is completed
- In most cases a core needle biopsy is adequate (it may need to be image guided depending on anatomical location of lesion)
- Ideally performed at centre which will do definitive management of disease

STAGING

- Local X Ray
- MRI
- CT scan chest
- Bone scan

CHONDROSARCOMA



Though the benefit is not certain

- dedifferentiated chondrosarcomas may receive multiagent chemotherapy similar to high grade osteosarcoma
- mesenchymal chondrosarcoma may receive multiagent chemotherapy similar to Ewing's sarcoma

It may be feasible to safely treat extremity grade I (low grade) chondrosarcoma with intralesional curettage without increasing the risk for local recurrence or metastatic disease

EXTREMITY SOFT TISSUE SARCOMA

Soft tissue sarcomas are a rare and heterogeneous group of tumors representing less than 1% of all adult malignancies. Sixty percent of soft-tissue sarcomas occur in the extremities making them the commonest site.

BIOPSY

- Biopsy diagnosis is mandatory
- Biopsy to be done only after all local imaging is completed
- In most cases a core needle biopsy is adequate (it may need to be image guided depending on anatomical location of lesion)
- Ideally performed at centre which will do definitive management of disease
- Immunohistochemistry confirmation desirable , may need additional cytogenetic and molecular studies

STAGING

- Local X ray
- MRI
- X ray chest / CT Scan (CT chest recommended in high grade sarcomas)
- USG abdomen pelvis in myxoid / round cell liposarcoma, angiosarcoma, epithelioid sarcoma and synovial sarcoma

Tumors referred after prior excision with inadequate or unknown margins need to be considered for re excision with similar guidelines as primary tumors

EXTREMITY SOFT TISSUE SARCOMA – METASTATIC AT PRESENTATION